

# BEIKE BIOTECHNOLOGY

## Patient Case Study

### Retinitis Pigmentosa (RP)

Male, 35 years old, Jan - Feb 2011

#### Background

Age: 35 years old

Sex: Male

Nationality: Taiwanese

Date of Admission: January 16, 2011

Date of Discharge: February 1, 2011

Treatment Center: Qingdao Chengyang Peoples Hospital, Qingdao, China

Diagnosis on Admission: Retinitis Pigmentosa (RP)

#### Condition On Admission

The patient's chief complaint was a loss of bilateral visual acuity and a decreasing visual field over the last 15 years. During physical examination upon arrival the movement of the patient's eyeballs was good, there was no spontaneous nystagmus, pupils were round and equal in size, and their reaction to light was very sensitive. There were no problems with the motor or sensory systems. The pre-treatment eye test revealed the visual acuity of the right eye to be VOD:0.5 and of the left eye to be VOS:0.6.

#### Treatment Schedule

Patient received 6 umbilical cord blood-derived stem cell (UCBSC) packets by intravenous (IV) injection, lumbar puncture (LP), and retrobulbar injection (RI) as per schedule below (please note that patient received two retrobulbar injections into the right eye):

Packet Number	Date	Cell Type	Delivery Method	Side Effects
1	January 19, 2011	UCBSC	IV	none reported
2 and 3	January 21, 2011	UCBSC	IV and LP	leg ache
4 and 5	January 24, 2011	UCBSC	RI and IV	none reported
6	January 28, 2011	UCBSC	RI	none reported

#### Condition On Discharge

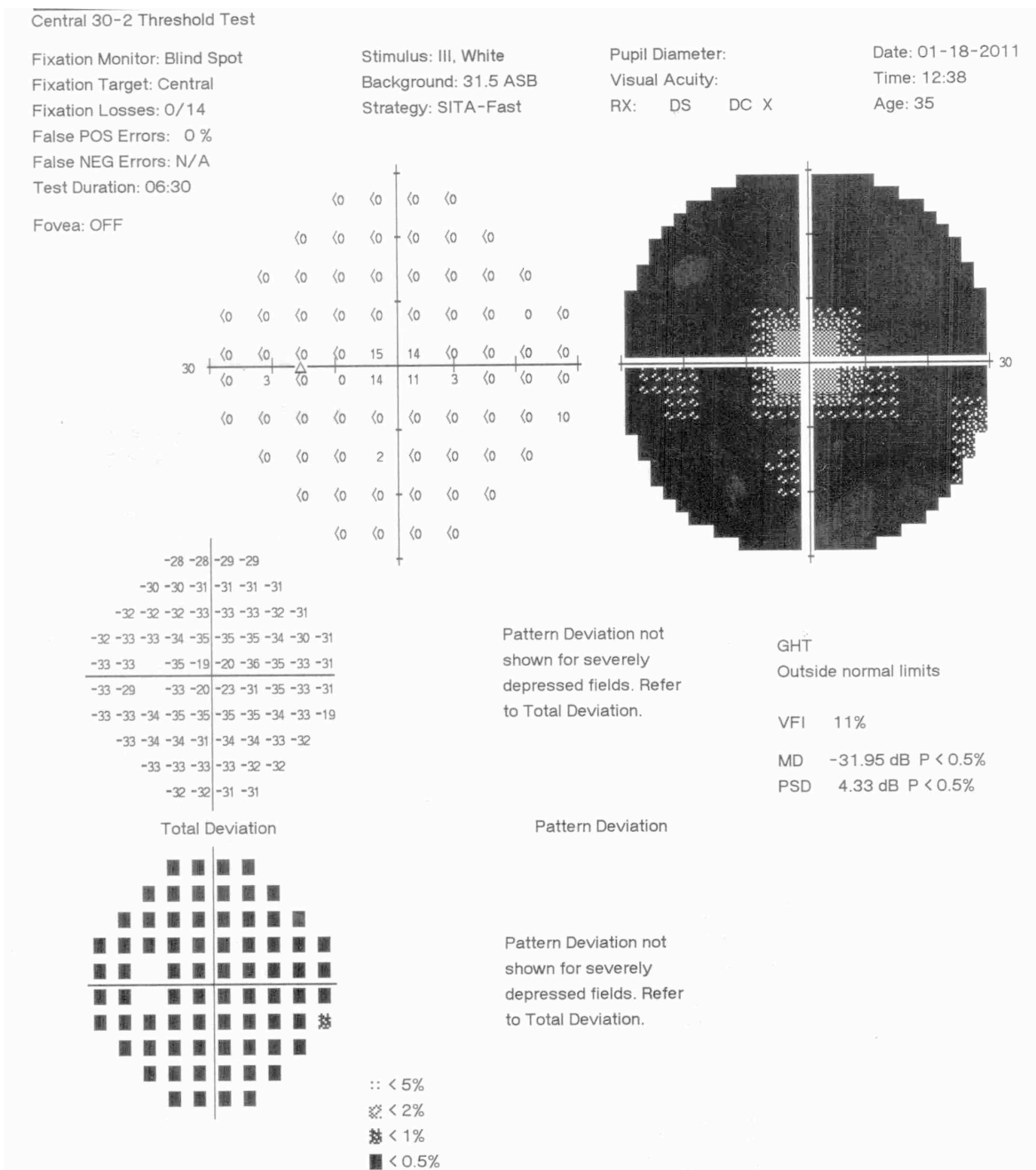
The patient felt well following his treatment and the leg ache following the first LP was fully resolved. The post treatment eye tests showed an increase in the patient's visual field and improvements in his visual acuity. Please see the tables on the next page for these results.

**Visual Acuity Results, recorded by the Shandong Eye Institute:**

Eye	Jan. 18, 2011 Pre-treatment	Jan. 29, 2011 Post-treatment
Right Eye	0.6	0.6
Left Eye	0.5	0.7

**Visual Field Results, recorded by the Shandong Eye Institute:**

Pre-Treatment, January 18, 2011, Left Eye





The patient wrote:

“My day vision (central vision) has improved greatly. Objects suddenly seem very sharp in contrast and very bright - though my color perception still feels the same as before. I personally feel that my day vision has improved a lot more than my night vision - though both of them showed very good improvements.”

“My night vision also shows good improvement - I can easily identify objects in the road in front of me which I could never see before. At night I feel I can see more contrast between different shades of black and gray. I can easily distinguish between a shadow and an actual object - before everything just appeared to be one shade of black.”

The below table is an excerpt taken from the patient’s own assessment on the follow up form:

Symptom	Parents’ Assessment of Improvement
Vision in left eye	Significant improvement
Vision in right eye	Significant improvement
Color vision	Moderate improvement
Night vision	Moderate improvement
Ability to see things clearly	Significant improvement
Ability to focus eyes quickly	Significant improvement
Ability to keep eyes focused for a long time	Moderate improvement
Ability to see things at a close distance	Moderate improvement
Ability to see things at a far distance	Moderate improvement

BEIKE BIOTECHNOLOGY CO., LTD.  
9th Floor, Zhongke Building, 1 South Street  
South Area, Shenzhen Hi-Tech Industrial Park  
Shenzhen, China 518057

Tel: +86-755-8630-9277 Email: info@beikebiotech.com  
Fax: +86-755-8630-9309 Web: www.beikebiotech.com